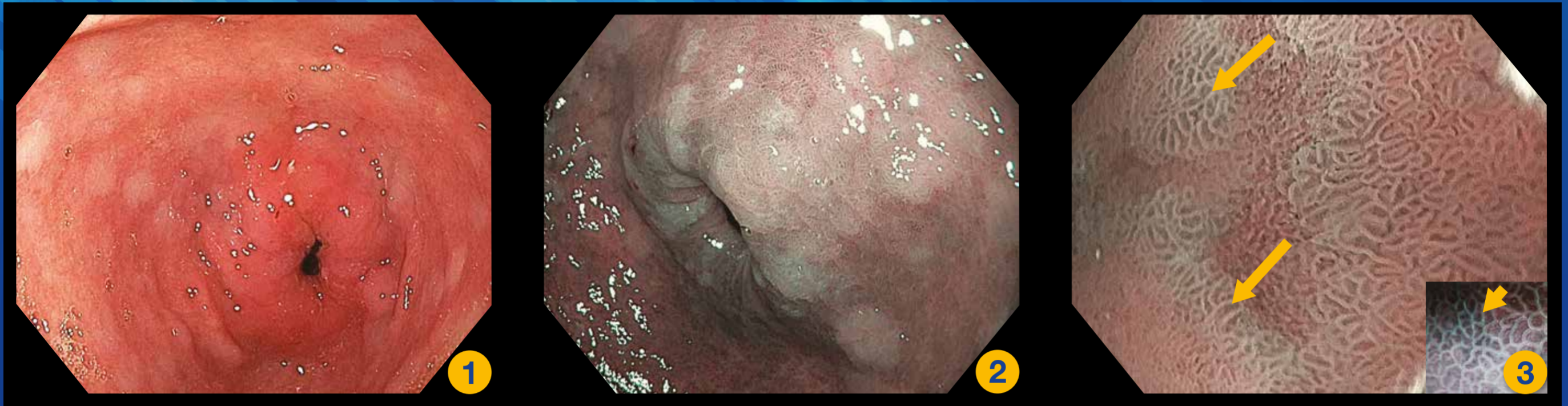

Diagnostic Criteria for Gastric Lesion

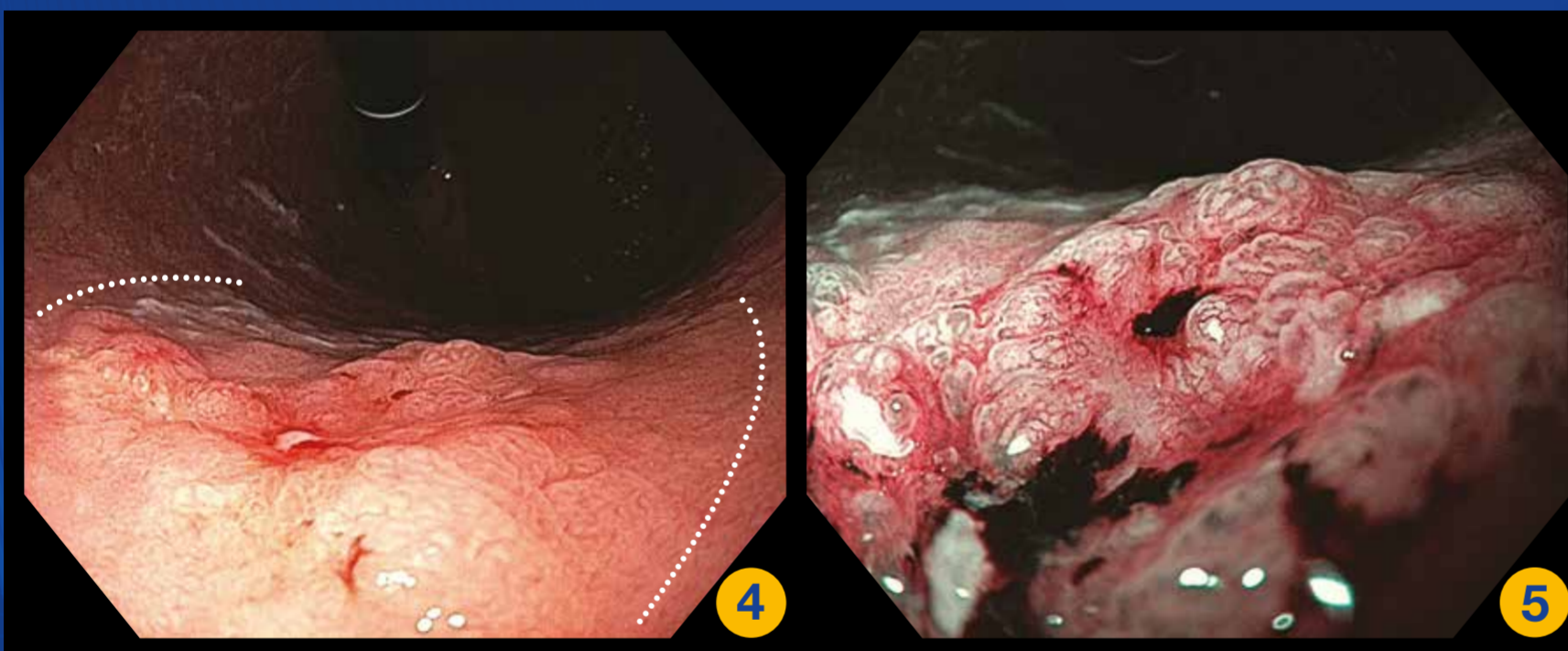


Gastric Intestinal metaplasia

Figure 1: White light endoscopy: Multiple discrete white patches at antrum

Figure 2: NBI: Multiple white patches at pre-pyloric area which are much better seen under NBI

Figure 3: Magnify NBI: Light blue crest (short arrow) and large long crest (long arrow)

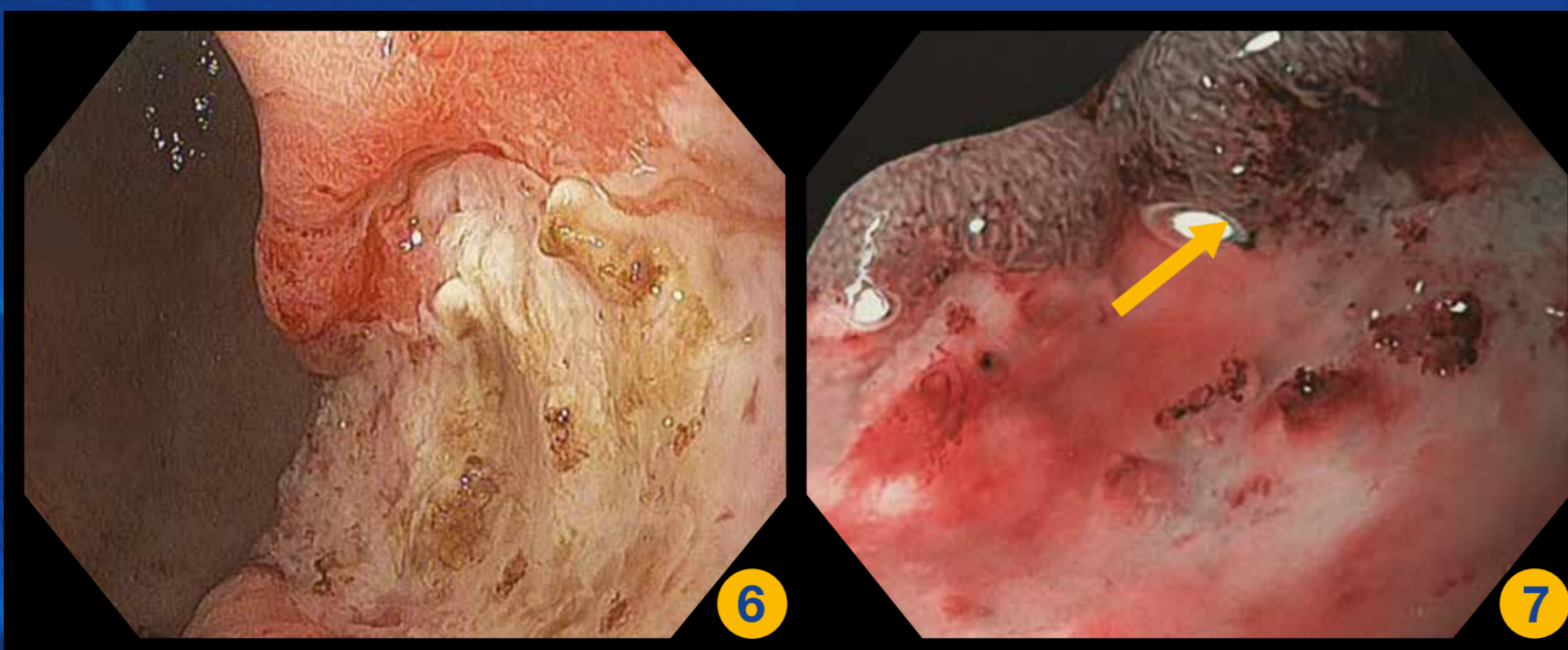


Gastric cancer; a candidate for endoscopic resection

Figure 4: White light endoscopy: Depressed lesion (0-IIc*) with central ulcer (0-III*) and margin elevation (0-IIa*)

Figure 5: Magnified NBI: Dilated and distorted microsurface with irregular and tortuous microvascular with blood oozing

*The Paris endoscopic classification of superficial neoplastic lesion of gastrointestinal tract



Gastric cancer; not a candidate for endoscopic resection

Figure 6: White light endoscopy: A large deep gastric ulcer and irregular border at the body of stomach

Figure 7: Magnifying NBI: Absent microsurface pattern and irregular, tortuous, different diameter in caliber of microvascular pattern at the focal area of the ulcer border. (arrow) The biopsy should be taken at this area